

# Sciatica: Treatment with Intradiscal and Intraforaminal Injections of Steroid and Oxygen-Ozone versus Steroid Only<sup>1</sup>

Massimo Gallucci, MD  
 Nicola Limbucci, MD  
 Luigi Zugaro, MD  
 Antonio Barile, MD  
 Emmanouil Stavroulis, MD  
 Alessandro Ricci, MD  
 Renato Galzio, MD  
 Carlo Masciocchi, MD

## Purpose:

To prospectively compare the clinical effectiveness of intraforaminal and intradiscal injections of a mixture of a steroid, a local anesthetic, and oxygen-ozone (O<sub>2</sub>-O<sub>3</sub>) (chemodiscolysis) versus intraforaminal and intradiscal injections of a steroid and an anesthetic in the management of radicular pain related to acute lumbar disk herniation.

## Materials and Methods:

Medical Ethical Committee approval and informed consent were obtained. One hundred fifty-nine patients (86 men, 73 women; age range, 18–71 years) were included and were randomly assigned to two groups. Seventy-seven patients (group A) underwent intradiscal and intraforaminal injections of a steroid and an anesthetic, and 82 patients (group B) underwent the same treatment with the addition of an O<sub>2</sub>-O<sub>3</sub> mixture. Procedures were performed with computed tomographic guidance. An Oswestry Low Back Pain Disability Questionnaire was administered before treatment and at intervals, the last at 6-month follow-up. Patients and clinicians were blinded as to which treatment was performed. Results were compared with the  $\chi^2$  test.

## Results:

After 6 months, treatment was successful in 36 (47%) patients in group A and in 61 (74%) patients in group B. The difference was significant ( $P < .01$ ).

## Conclusion:

Intraforaminal and intradiscal injections of a steroid, an anesthetic, and O<sub>2</sub>-O<sub>3</sub> are more effective at 6 months than injections of only a steroid and an anesthetic in the same sites.

© RSNA, 2007

<sup>1</sup> From the Departments of Radiology (M.G., N.L., L.Z., A.B., E.S., C.M.) and Neurosurgery (A.R., R.G.), University of L'Aquila, S Salvatore Hospital, Coppito, 67100 L'Aquila, Italy. Received November 28, 2005; revision requested January 18, 2006; revision received March 1; accepted April 4; final version accepted, June 19. **Address correspondence to N.L.** (e-mail: [niclimb@libero.it](mailto:niclimb@libero.it)).

Low back pain and sciatica are said to affect most of the population at least once during a lifetime (1). Nevertheless, the natural history of lumbar disk herniation is favorable: Improvement of symptoms is the norm, and most episodes resolve spontaneously or after conservative therapy (2,3). The natural history of lumbar disk herniation has been elucidated by means of serial imaging studies, which showed spontaneous clinical and anatomic resolution in 67%–76% of patients after 1 year (4–8). Therefore, an invasive approach is reserved for patients failing to respond to conservative treatment.

Surgery is less invasive than it was in the past because of new microsurgical techniques. However, its success rate is not optimal: Pain resolution is present in no more than 80%–85% of patients (9), and a failed back surgery syndrome develops in 10%–40% of patients (10).

In the past decades, many new minimally invasive image-guided interventional techniques have been developed to reduce the need for surgery and to improve the quality of life of patients requiring systemic drugs (11–13). Yet, few of these treatments have been tested in controlled randomized studies.

A recently proposed treatment for lumbar disk herniation is chemodiscolysis by means of percutaneous intradiscal oxygen-ozone ( $O_2-O_3$ ) injection. The effectiveness of this treatment has been tested in large clinical studies, findings of which have shown a positive outcome in 70%–80% of patients (14–18). Findings of a randomized controlled study (19) to assess the effectiveness of intraforaminal injection of  $O_2-O_3$  versus steroids have been recently published, with  $O_2-O_3$  injection being more effective than steroids.

The purpose of our study was to prospectively compare the clinical effective-

ness of intraforaminal and intradiscal injections of a mixture of a steroid, a local anesthetic, and  $O_2-O_3$  (chemodiscolysis) versus intraforaminal and intradiscal injections of a steroid and an anesthetic in the management of radicular pain related to acute lumbar disk herniation.

## Materials and Methods

### Patients

The study protocol was approved by the Medical Ethical Committee of our institution. We obtained informed consent from all patients. From March 2004 to April 2005 (14 months), we treated 159 patients (86 men, 73 women; age range, 18–71 years) with lumbar disk herniation (L3-4, 23 patients; L4-5, 61 patients; L5-S1, 75 patients) and radicular pain. The mean duration of radicular pain at the time of treatment was 15 weeks. Preliminary clinical evaluation was performed by two experienced neurosurgeons (R.G., 25 years experience; A.R., 10 years experience). Moreover, all patients underwent computed tomography (CT) or magnetic resonance (MR) imaging.

Inclusion criteria comprised monoradicular pain, lumbar disk herniation on CT or MR images, herniation site congruous with the neurologic level, and Oswestry Disability Index (20) greater than 30%. All patients complained of pain for at least 8 weeks. They had received conservative therapy (physiotherapy and/or nonsteroidal antiinflammatory drugs and/or intramuscular steroids) for 2–4 weeks, with no or poor clinical improvement.

Exclusion criteria comprised pregnancy, referred allergy to proposed drugs, and major neurologic deficits. We also excluded any patients who had clinically diagnosed syndromes that are able to mimic the symptoms of a lumbar disk herniation: facet syndrome, sacroileitis, bone lesions (infective, inflammatory, or neoplastic), or previous spine surgery.

The level to be treated was chosen on the basis of results from a neurologic examination performed by the neurosurgeons and correspondence between

imaging and clinical findings. Discography was performed only in few patients at the beginning of our practice, but we abandoned this procedure. According to our experience and the literature (21), discography does not add important information because only patients with discogenic pain are identified with this procedure. Moreover, a contrast agent injected during discography fills the potential intradiscal space that may be used for therapeutic agents (ie, steroids and  $O_2-O_3$ ), which prevents injection of the optimal amount of these drugs. However, in our experience,  $O_2-O_3$  itself has a discographic effect.

The 159 enrolled patients were all the ones who met our criteria and who were treated during the study time. The patients were randomly assigned to one of two groups (A and B) by means of a randomization grid. Group A included 77 patients (43 men and 34 women; mean age, 41 years), and group B included 82 patients (45 men and 37 women; mean age, 40 years) (Table). Group A underwent intraforaminal and intradiscal injections of 2 mL of triamcinolone acetonide (40 mg/mL Kenacort; Bristol-Myers Squibb, Sermoneta, Italy), with 1 mL injected in the epidural space and 1 mL injected inside the disk, and 2–4 mL of 2% ropivacaine (Naropina; AstraZeneca, Basiglio, Italy), about 2 mL injected in the epidural space and 1 mL injected inside the disk. Group B received the same treatment with the addition of an  $O_2-O_3$  mixture,

### Published online before print

10.1148/radiol.2423051934

Radiology 2007; 242:907–913

### Abbreviation:

CI = confidence interval

### Author contributions:

Guarantors of integrity of entire study, M.G., C.M.; study concepts/study design or data acquisition or data analysis/interpretation, all authors; manuscript drafting or manuscript revision for important intellectual content, all authors; approval of final version of submitted manuscript, all authors; literature research, M.G., N.L., A.R.; clinical studies, M.G., N.L., A.R., R.G.; experimental studies, M.G., N.L., L.Z., A.B., E.S.; statistical analysis, N.L., L.Z., A.B., E.S.; and manuscript editing, N.L., C.M.

Authors stated no financial relationship to disclose.

## Advance in Knowledge

- Perigangliar and intradiscal injections of oxygen-ozone and steroids are more effective than steroid and anesthetic injections.

with an ozone concentration of 28  $\mu\text{g}/\text{mL}$ . We injected 5–7 mL of  $\text{O}_2\text{-O}_3$  at intraforaminal level (mean, 6.5 mL) and 5–7 mL of  $\text{O}_2\text{-O}_3$  inside the disk (mean, 5.8 mL). We chose a steroid injection for comparison because of the effectiveness of this treatment and the similar degree of invasiveness of both interventions (22,23). Patients were blinded as to whether they had received  $\text{O}_2\text{-O}_3$  as part of the treatment.

### Procedures

The procedures were always performed on an outpatient basis by two neuroradiologists (M.G., 8 years experience in spinal interventions; N.L., 2 years experience). Before every procedure, the patients received premedication with intravenously administered 1 g of cefazoline (Totacef; Bristol-Myers Squibb), 30 mg of ketorolac (Toradol; Recordati, Milan, Italy), and 50 mg of ranitidine (Ranidil; Menarini, Florence, Italy). All procedures were performed with CT guidance (Somatom Plus 4; Siemens Medical Systems, Erlangen, Germany) with the patient in the prone position. Transverse scans (3 mm thick) were used to choose the needle path and to calculate the entry point.

The  $\text{O}_2\text{-O}_3$  gas mixture was achieved by using an ozone generator (OZO2 Futura; Alnitec, Cremona, Italy). Intradiscal and intraforaminal injections were administered with a paravertebral approach in 147 (92.4%) patients and an interlaminar approach in

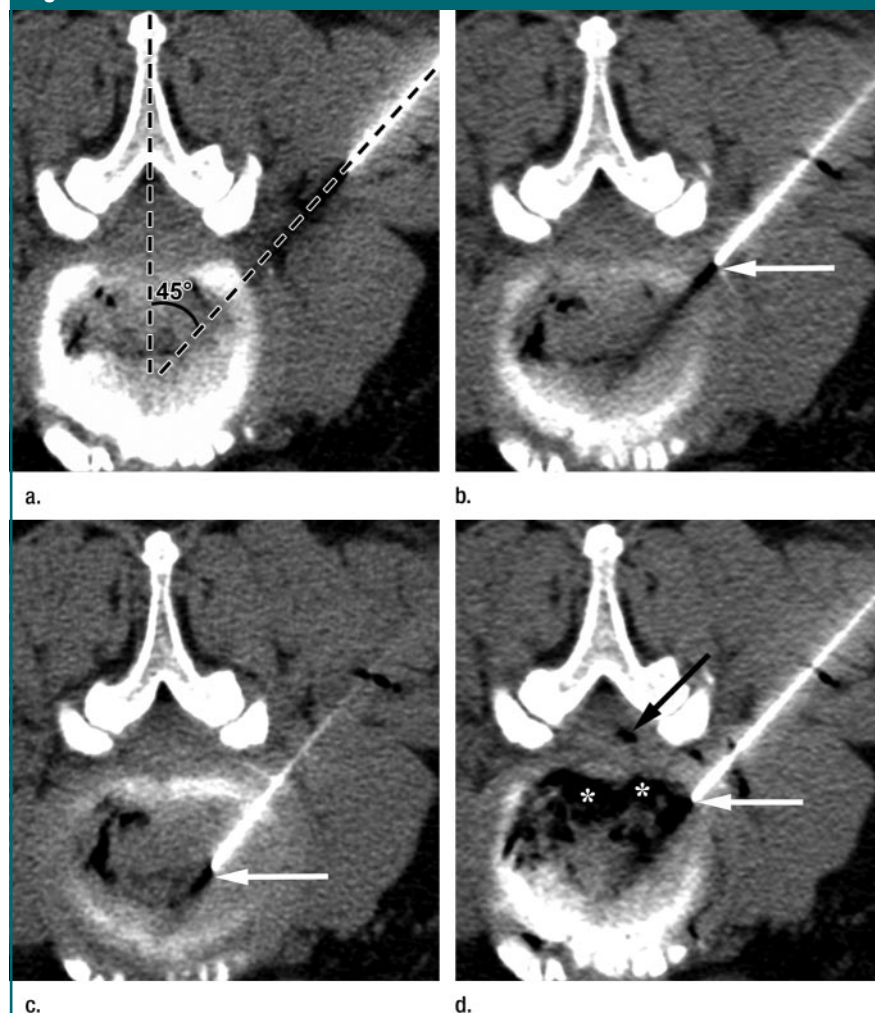
12 (7.6%) patients by using a 9- or 15-cm 22-gauge spinal needle. The side of the injection was chosen on the basis of the main location of symptoms.

After local anesthesia, the needle was advanced to the intraforaminal space, with an angle usually between  $45^\circ$  and  $60^\circ$ , following a needle tip position with use of CT scans (Fig 1a). After confirmation of the position, the drugs were injected at this level (Fig 1b). The needle was subsequently advanced toward the disk to inject the drugs inside

the nucleus pulposus. When the needle entered the disk, a soft resistance was felt. Before injection inside the disk, a CT scan was used to confirm that the needle tip was inside the nucleus pulposus to avoid injection into the outer annulus (Fig 1c). The drugs were slowly injected inside the disk.

In group B,  $\text{O}_2\text{-O}_3$  was injected immediately after anesthetic and steroid injections. A mild resistance was usually felt during  $\text{O}_2\text{-O}_3$  injection; if the resistance was strong, the injection was stopped. A

**Figure 1**



**Figure 1:** Transverse CT images of consecutive phases of  $\text{O}_2\text{-O}_3$  chemodiscolysis with right paravertebral approach at L4-5 level in 65-year-old man in prone position. (a) Entry path with a  $45^\circ$  angle. (b) Tip of the needle (arrow) is in periradicular position. (c) Needle is advanced inside the disk following the same path; the position is confirmed by evidence of needle tip (arrow). (d) Distribution of gas after intradiscal and periradicular injections; the needle is still on site (white arrow). The  $\text{O}_2\text{-O}_3$  mixture is distributed inside the disk (\*) and in epidural space (black arrow).

### Patient Characteristics

Characteristic	Group A	Group B
No. of patients	77	82
Men/women	43:34	45:37
Mean age (y)	41	40
L3-4 herniation	12 (16)	11 (13)
L4-5 herniation	27 (35)	31 (38)
L5-S1 herniation	38 (49)	40 (49)
Mean ODI score at baseline (%)*	57.5	58.4
Mean surgical time (min)	27	30

Note.—Unless otherwise indicated, data are numbers of patients. Data in parentheses are percentages.

\* ODI = Oswestry Disability Index.

CT scan was acquired to evaluate eventual complications and O<sub>2</sub>-O<sub>3</sub> distribution. O<sub>2</sub>-O<sub>3</sub> delivery was considered satisfactory when the gas was homogeneously distributed inside the nucleus pulposus and when it showed diffusion in the epidural space, with involvement of the periganglionic space (Fig 1d). If epidural diffusion was absent or poor (gas only near the root and not in the epidural space, or vice versa), the needle was pulled out of the disk and was repositioned deeper in the foramen or in the epidural space, and O<sub>2</sub>-O<sub>3</sub> was injected again. Epidural gas diffusion could help confirm the proper positioning. After this last evaluation, the needle was removed and the procedure was concluded. The interlaminar access was only performed when the lumbar bone anatomy made needle positioning in the center of the disk impossible with a paravertebral approach and conventional spinal needles. CT guidance always pre-

vented injections into or puncture of the dural sac (Fig 2).

Overall, the average injected volume in group A was 3 mL at intraforaminal level and 2 mL inside the disk. In group B, the average injected volume was 9.5 mL at the intraforaminal level and 6.8 mL inside the disk. The average injected volume of O<sub>2</sub>-O<sub>3</sub> in group B patients was 12.3 mL. Mean surgical time was 27 minutes (range, 12–40 minutes) for group A and 30 minutes (range, 12–45 minutes) for group B. After treatment, the patients rested in the supine decubitus position for 2 hours. At discharge, the patients were advised to take a 4-day rest and to gradually resume motion activity.

#### Outcome Evaluation

To determine the effectiveness of the procedures, a 6-month follow-up was performed. We administered the Oswestry

Low Back Pain Disability Questionnaire (24) to all patients the day of the procedure, 2 weeks later, and 3 and 6 months later. Data about possible complications were also collected. The questionnaire was administered by two individuals (E.S., L.Z.) who were blinded to patient distribution in the two groups. During follow-up, the questionnaire was administered by phone. Every patient was randomly assigned to one of the two clinicians, with each clinician administering the questionnaire to each of the patients in the subset over the full course of follow-up. Clinician A (E.S.) interviewed 37 (48%) group A patients and 39 (47%) group B patients. Clinician B (L.Z.) interviewed 40 (52%) group A patients and 43 (52%) group B patients.

The results of the questionnaire were used to calculate the Oswestry Disability Index, which was applied to assess clinical outcome. The response to treatment was considered binary; classified as successful if the Oswestry Disability Index was no greater than 20% at follow-up, and unsuccessful otherwise. Ten group B patients with unsuccessful results had second intraforaminal and intradiscal O<sub>2</sub>-O<sub>3</sub> injections, and 6-month follow-up was performed.

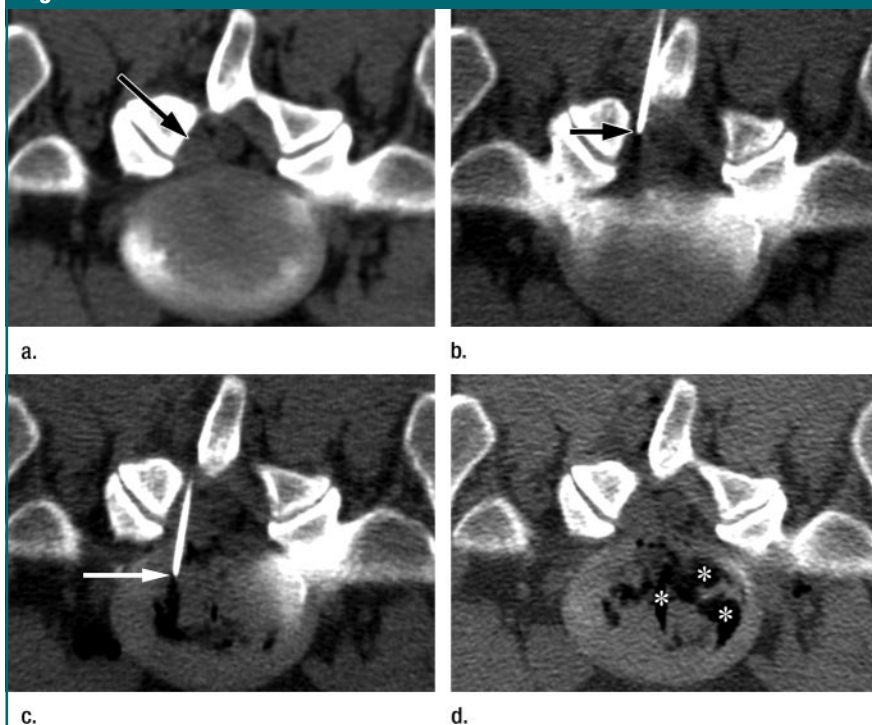
During and after the procedures, all patients were carefully evaluated by the neuroradiologist who performed the procedure in order to recognize any complications. During phone consultation, patients were asked to report any possible late complication. Considered complications were allergic reactions, high or low blood pressure induced by drugs, infections, and permanent neurologic deficits.

#### Statistical Analysis

An evaluation of the success rate was performed for both groups on the basis of the Oswestry Disability Index. The results of the Oswestry pain questionnaire were entered in a database. The success rates at 2-week, 3-month, and 6-month follow-up for groups A and B were compared by means of the  $\chi^2$  test.  $P < .01$  was considered to indicate a statistically significant difference.

The success rate of group B patients who underwent a second intraforaminal

**Figure 2**



**Figure 2:** Transverse CT images of consecutive phases of O<sub>2</sub>-O<sub>3</sub> chemodiscolysis with left interlaminar approach at L5-S1 level in 21-year-old man in prone position. (a) Preprocedural image shows right paracentral disk extrusion (arrow). (b) Tip of needle (arrow) is positioned close to the herniation; dural theca is not located along needle entry path. (c) Needle (arrow) is inside the disk and its position is extrathecal. After further needle entry, drugs are injected. (d) Postprocedural image shows wide distribution of gas (\*) inside the disk.

and intradiscal O<sub>2</sub>-O<sub>3</sub> injection session was calculated; however, no formal statistic was used because of the low number of patients. The success and complication rates of the patients treated with the interlaminar approach were also considered separately to evaluate both the effectiveness and the safety of this approach.

The software used for statistical analysis was Stata (version 8.2; Stata-Corp, College Station, Tex).

## Results

### Group A

In group A, the treatment was a success in 69 (90%) of 77 patients (95% confidence interval [CI]: 80.6%, 95.4%) after 2 weeks, 52 (67%) patients (95% CI: 55.9%, 77.8%) after 3 months, and 36 (47%) patients (95% CI: 35.3%, 58.5%) after 6 months. The treatment was unsuccessful in 41 (53%) patients after 6 months.

### Group B

In group B, the treatment was a success in 72 (88%) of 82 patients (95% CI: 78.8%, 93.4%) after 2 weeks, 64 (78%) patients (95% CI: 67.5%, 86.4%) after 3 months, and 61 (74%) patients (95% CI: 63.6%, 83.3%) after 6 months. At 6-month follow-up, the treatment was unsuccessful in the remaining 21 (26%) group B patients. Among the 10 group B patients who underwent a second O<sub>2</sub>-O<sub>3</sub> procedure, the 6-month follow-up revealed a satisfactory outcome in five (50%) patients.

### Groups A and B Comparison

The statistical analysis with  $\chi^2$  test showed that the different outcome at 2 weeks was not significant ( $\chi^2 = 0.13$ ,  $P = .72$ ). After 3 months, the difference was also not significant ( $\chi^2 = 2.23$ ,  $P = .136$ ). On the contrary, the  $\chi^2$  test showed that after 6 months, the success rate difference between group A and group B was statistically significant ( $\chi^2 = 12.75$ ,  $P < .001$ ) (Fig 3).

### Interlaminar Approach

Five of the 12 patients treated by means of an interlaminar approach were part

of group A, and seven were part of group B. After 6 months, the treatment was successful in two (40%) of five group A patients and in five (71%) of seven group B patients.

### Complications

During or after the procedures, no major or minor complications were observed.

## Discussion

In our series, we administered an intradiscal steroid and an anesthetic. Intradiscal anesthetics are useful for discogenic pain diagnosis and treatment (20). Intradiscal steroid injection is not a definitively established treatment, and studies have shown discordant results (25,26). Intradiscal steroids and anesthetics can be useful mainly in patients with reactive endplate changes (25). Pain reduction can also depend on the block of Luschka nerve fibers that enter the annulus.

Periganglionic and intradiscal injections of O<sub>2</sub>-O<sub>3</sub> have been proposed since the late 1990s as a treatment for lumbar disk herniation (14–18). Ozone is an unstable form of oxygen that, in water, reacts with organic molecules containing double or triple bonds: Ozone causes an oxide reduction called ozonolysis. This reaction involves mainly molecules for which ozone has affinity (27). Intradiscal O<sub>2</sub>-O<sub>3</sub> mixture injection produces a chemodiscolysis, with ozonolysis of nucleus pulposus proteoglycans, loss of water, and dehydration. Progressive degeneration with fibrous replacement occurs followed, finally, by disk shrinkage. In this way, chemodiscolysis leads to loss of disk volume and direct reduction of root compression. Chemodiscolysis has been shown experimentally in rabbit and human disks, with histopathologic evidence of dehydration of the fibrillary matrix of the nucleus pulposus, vacuole formation, and collagen fragmentation (15,28,29). The reduction of herniated disk volume decreases root edema and venous stasis, stopping the demyelination process (28).

The mixture also has analgesic and antiinflammatory effects. Ozone, by means of direct ozonolysis, inhibits the

Figure 3

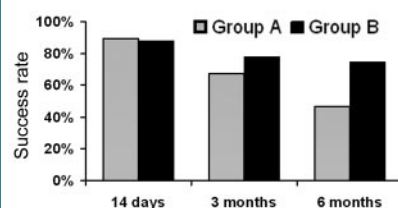


Figure 3: Graph shows outcomes of group A and group B patients whose treatment was deemed a success according to their responses to the Oswestry pain questionnaire. At 2 weeks and 3 months, outcome of group B patients is similar to that of group A patients. Difference becomes appreciable after 6-month follow-up, when the procedure was successful in 74% of group B and in 47% of group A patients ( $P < .01$ ).

synthesis and release of prostaglandins, bradykinin, and various algogenic molecules (27). Moreover, ozone increases the release of antagonists of proinflammatory cytokines (27). Thus, O<sub>2</sub>-O<sub>3</sub> can solve or decrease chemical radiculitis (28,30). The effect of ozone on chemical radiculitis can also explain the clinical effectiveness of intraforaminal O<sub>2</sub>-O<sub>3</sub> injection without intradiscal therapy (19).

The reported effectiveness of the procedure is promising, with clinical success in 70%–80% of patients (14–18). In our practice, we inject a steroid and a local anesthetic in addition to the O<sub>2</sub>-O<sub>3</sub> mixture, because the combination of these agents has been proved to be more effective than the injection of the O<sub>2</sub>-O<sub>3</sub> mixture alone (15).

Group B had a successful outcome in 74% of patients after 6 months, while group A had a successful outcome in 47% of patients. The statistical analysis demonstrated that this difference was significant ( $P < .01$ ); consequently, the combined injection of O<sub>2</sub>-O<sub>3</sub>, a steroid, and an anesthetic at the intradiscal and intraforaminal levels should be considered more effective than a simple steroid and anesthetic injection. The injection of O<sub>2</sub>-O<sub>3</sub> is the only difference between the two treatments we compared; therefore, the better outcome of group B patients should be due to the pharmacologic actions of O<sub>2</sub>-O<sub>3</sub>. Our results are simi-

lar to those reported in other studies (14–18) in which intradiscal O<sub>2</sub>-O<sub>3</sub> injections were not compared with other percutaneous interventional treatments. Small differences between our and other studies may be related to patient selection and evaluation methods.

We observed that 2 weeks and 3 months after the procedure, the difference in success rate between group A and group B was not significant. The difference became significant only after 6 months, probably because the effectiveness of steroids and anesthetics administered to both groups is temporary, while O<sub>2</sub>-O<sub>3</sub> has long-acting effects. Therefore, in comparison to conventional steroid injections, O<sub>2</sub>-O<sub>3</sub> therapy appears to be a more effective treatment.

The 6-month success rate of group B patients is similar to that obtained with other percutaneous intradiscal interventions (11–13). Intradiscal and intraforaminal O<sub>2</sub>-O<sub>3</sub> injections are less invasive for many reasons, such as a narrower needle and absence of probes and of toxicity. O<sub>2</sub>-O<sub>3</sub> therapy is also cost-effective, because it can be performed on an outpatient basis and thus has favorable implications for cost, as does the equipment needed for the procedure. In our experience, there were no complications, which helped confirm that O<sub>2</sub>-O<sub>3</sub> chemodiscolysis is a safe procedure (14–18).

In our series, we performed all procedures with CT guidance instead of fluoroscopy, as was done in other studies (18). The main reason was practicality, since at our institution we have three CT units. There is no published evidence that CT guidance is superior to fluoroscopy. However, in our opinion, this approach ensures more precise needle positioning in the central part of the disk and reduces the risk of complications and incorrect injection sites. Moreover, CT allows verification of correct gas diffusion, which is more difficult with fluoroscopy. Another advantage of CT is the lack of operator exposure.

The main limitations of our study were the low number of enrolled patients and the short follow-up interval.

Future studies are necessary to demonstrate whether O<sub>2</sub>-O<sub>3</sub> therapy effects are limited over time.

In conclusion, intraforaminal and intradiscal injections of an O<sub>2</sub>-O<sub>3</sub> mixture, a steroid, and an anesthetic with CT guidance lead to rapid pain relief, with good outcome in most patients. This treatment is easy to perform and is safe. Moreover, it is more effective than the injections of pure steroids and anesthetic in the same sites; therefore, O<sub>2</sub>-O<sub>3</sub> seems to play a role in pain relief. In our opinion, O<sub>2</sub>-O<sub>3</sub> chemodiscolysis should be regarded as a useful treatment for the management of lumbar disk herniation.

**Acknowledgment:** The authors thank Dr Angela Martella for translation of the manuscript.

## References

1. Deyo RA, Weinstein JN. Low back pain. *N Engl J Med* 2001;344:363–370.
2. Saal JA. Natural history and nonoperative treatment of lumbar disc herniation. *Spine* 1996;21(suppl 24):2S–9S.
3. Komori H, Shinomiya K, Nakai O, Yamaura I, Takeda S, Furuya K. The natural history of herniated nucleus pulposus with radiculopathy. *Spine* 1996;21:225–229.
4. Bozzao A, Gallucci M, Masciocchi C, Aprile I, Barile A, Passariello R. Lumbar disk herniation: MR imaging assessment of natural history in patients treated without surgery. *Radiology* 1992;185:135–141.
5. Bush K, Cowan N, Katz DE, Gishen P. The natural history of sciatica associated with disc pathology: a prospective study with clinical and independent radiologic follow-up. *Spine* 1992;17:1205–1212.
6. Delauche-Cavallier MC, Budet C, Laredo JD, et al. Lumbar disc herniation: computed tomography scan changes after conservative treatment of nerve root compression. *Spine* 1992;17:927–933.
7. Gallucci M, Bozzao A, Orlandi B, Manetta R, Brughitta G, Lupattelli L. Does postcontrast MR enhancement in lumbar disk herniation have prognostic value? *J Comput Assist Tomogr* 1995;19:34–38.
8. Splendiani A, Puglielli E, De Amicis R, Barile A, Masciocchi C, Gallucci M. Spontaneous resolution of lumbar disk herniation: predictive signs for prognostic evaluation. *Neuroradiology* 2004;46:916–922.
9. Spaziant R. La terapia chirurgica nel conflitto disco-radicolare. *Riv Neuroradiol* 1997;10:545–550.
10. Osborn AG. Nonneoplastic disorders of the spine and spinal cord. In: *Diagnostic neuroradiology*. St Louis, Mo: Mosby, 1994; 820–875.
11. Choy DS, Ascher PW, Ranu HS, et al. Percutaneous laser disc decompression: a new therapeutic modality. *Spine* 1992;17:949–956. [Published correction appears in *Spine* 1993;18:939.]
12. Onik G, Helms CA, Ginsburg L, Hoaglund FT, Morris J. Percutaneous lumbar discectomy using a new aspiration probe. *AJR Am J Roentgenol* 1985;144:1137–1140.
13. Wittenberg RH, Oppel S, Rubenthaler FA, Steffen R. Five-year results from chemonucleolysis with chymopapain or collagenase: a prospective randomized study. *Spine* 2001;26:1835–1841.
14. D'Erme M, Scarchilli A, Artale AM, Pasquali Lasagni M. Ozonotherapy in lumbar sciatic pain [in Italian]. *Radiol Med (Torino)* 1998;95:21–24.
15. Andreula CF, Simonetti L, De Santis F, Agati R, Ricci R, Leonardi M. Minimally invasive oxygen-ozone therapy for lumbar disk herniation. *AJNR Am J Neuroradiol* 2003;24:996–1000.
16. Muto M, Andreula C, Leonardi M. Treatment of herniated lumbar disc by intradiscal and intraforaminal oxygen-ozone (O<sub>2</sub>-O<sub>3</sub>) injection. *J Neuroradiol* 2004;31:183–189.
17. Muto M, Avella F. Percutaneous treatment of herniated lumbar disc by intradiscal oxygen-ozone injection. *Intervent Neuroradiol* 1998;4:279–286.
18. Paradiso R, Alexandre A. The different outcomes of patients with disc herniation treated either by microdiscectomy, or by intradiscal ozone injection. *Acta Neurochir Suppl* 2005;92:139–142.
19. Bonetti M, Fontana A, Cotticelli B, Volta GD, Guindani M, Leonardi M. Intraforaminal O(2)-O(3) versus periradicular steroid infiltrations in lower back pain: randomized controlled study. *AJNR Am J Neuroradiol* 2005;26:996–1000.
20. Fairbank JC, Pynsent PB. The Oswestry Disability Index. *Spine* 2000;25:2940–2952.
21. Milette PC, Fontaine S, Lepanto L, Breton G. Radiating pain to the lower extremities caused by lumbar disk rupture without spinal nerve root involvement. *AJNR Am J Neuroradiol* 1995;16:1605–1613.
22. Zennaro H, Dousset V, Viaud B, et al. Periganglionic foraminal steroid injections per-

- formed under CT control. *AJNR Am J Neuroradiol* 1998;19:349-352.
23. Carrette S, Leclaire R, Marcoux S, et al. Epidural corticosteroid injections for sciatica due to herniated nucleus pulposus. *N Engl J Med* 1997;336:1634-1640.
24. Fairbank JC, Couper J, Davies JB, O'Brien JP. The Oswestry Low Back Pain Disability Questionnaire. *Physiotherapy* 1980;66:271-273.
25. Buttermann GR. The effect of spinal steroid injections for degenerative disc disease. *Spine J* 2004;4:495-505.
26. Khot A, Bowditch M, Powell J, Sharp D. The use of intradiscal steroid therapy for lumbar spinal discogenic pain: a randomized controlled trial. *Spine* 2004;29:833-836.
27. Richelmi P, Valdenassi L, Bertè F. Basi farmacologiche dell'azione dell'ossigeno-ozono terapia. *Riv Neuroradiol* 2001;14(suppl 1):17-22.
28. Iliakis E, Valadakis V, Vynios DH, Tisiganos CP, Agapitos E. Rationalization of the activity of medical ozone on intervertebral disc: a histological and biochemical study. *Riv Neuroradiol* 2001;14(suppl 1):23-30.
29. Leonardi M, Simonetti L, Barbara C. Effetti dell'ozono sul nucleo polposo: reperti anatomo-patologici su un caso operato. *Riv Neuroradiol* 2001;14(suppl 1):57-59.
30. Bocci V, Luzzi E, Corradeschi F, Palesu L, Di Stefano A. Studies on the biological effects of ozone. III. An attempt to define conditions for optimal induction of cytokines. *Lymphokine Cytokine Res* 1993;12:121-126.